



**PRESENTING CLINICAL SIGNS**

**DATE** History: Pre-breeding evaluation. Mother had HCM. No murmur.

**ECHOCARDIOGRAPHIC FINDINGS**

7/26/22 2D, M-mode, and Doppler study.

**PERFORMED BY:**

Dr. Meredith Swart

Left atrial size is normal. The mitral valve is normal. Left ventricular wall thickness is normal. Left ventricular internal dimensions are normal. Left ventricular systolic function is mildly hyperdynamic. The aorta and aortic valve are normal. Right atrial and right ventricular dimensions are normal. The tricuspid valve is normal. The pulmonary artery and pulmonic valve are normal. No shunting lesions are visualized. No pericardial effusion or cardiac masses are seen.

**INTERPRETED BY**

Keith Blass, DVM,  
MS, DACVIM  
(Cardiology)

LA - 13.2 mm  
IVSd - 4.6 mm  
LVPWd - 4.6 mm  
LVIDd - 12.8 mm  
LVIDs - 5.8 mm  
FS - 54.7%  
RA - 9.3 mm  
LVOT - 0.92 m/s

**PATIENT**

Pearl Arguin

**ASSESSMENT/RECOMMENDATIONS**

Normal echocardiogram

**SPECIES**

Feline

This examination demonstrates no evidence of structural heart disease. As such, no contraindication to breeding Pearl is appreciated in the image set. Having said that, it is possible that Pearl could develop HCM as she ages, therefore, yearly NT-proBNP levels and/or echocardiography should be considered to make sure that she remains free of disease.

**BREED**

Sphinx

No therapy is recommended based on this exam.

**SEX**

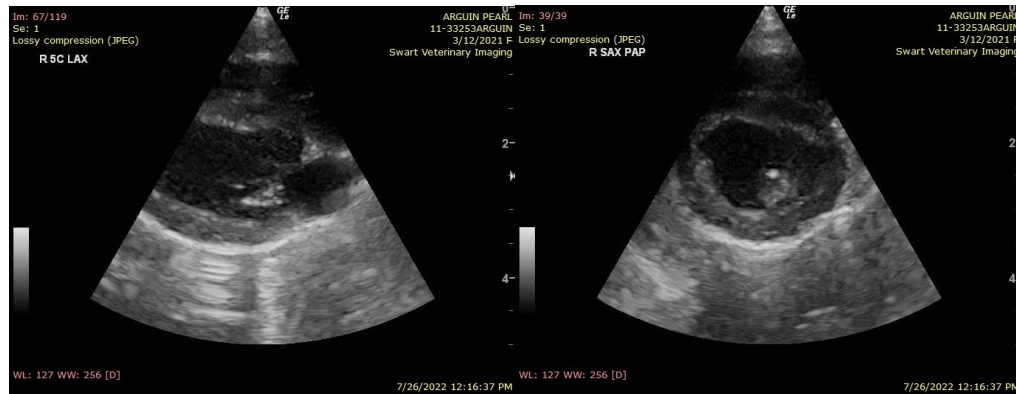FI

**AGE**

16 mo

**WEIGHT**

5.6 lb



**HOSPITAL NAME**

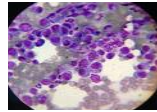
Swart Veterinary  
Imaging

The information and recommendations provided are based on the images presented by the referring veterinarian. No evaluation can be communicated regarding pathology that was not visible in the image/video clips provided.

Thank you for this referral. If the clinical or image interpretation does not parallel your findings or if I can be of any further assistance please contact me.

**REFERRING VET**

Dr. Swart



**DATE** Keith Blass, DVM, MS, DACVIM (Cardiology)  
KeithBlass@gmail.com  
631-804-5754

7/26/22

**PERFORMED BY:**

Dr. Meredith Swart

**INTERPRETED BY**

Keith Blass, DVM,  
MS, DACVIM  
(Cardiology)

**PATIENT**

Pearl Arguin

**SPECIES**

Feline

**BREED**

Sphinx

**SEX**

FI

**AGE**

16 mo

**WEIGHT**

5.6 lb

**HOSPITAL NAME**

Swart Veterinary  
Imaging

**REFERRING VET**

Dr. Swart